

## CASE REPORT

## PEER REVIEWED | OPEN ACCESS

# A severe case of acidosis with concomitant use of avapritinib and metformin requiring emergent hemodialysis

Babajide Adio, Sepideh Darbandi

## ABSTRACT

**Introduction:** Avapritinib (Ayvakit), a tyrosine kinase inhibitor (TKI), has been recently approved for the treatment of adult patients with unresectable or metastatic gastrointestinal stromal tumor (GIST) who have a platelet-derived growth factor receptor alpha (PDGFRA) exon 18 mutation. New therapeutic agents for malignancy, specifically TKIs, have allowed for major advances in treatment options. **Case Report:** A 56-year-old male with past medical history significant for GIST of the stomach, who was recently started on a new trial medication ayvakit, presented with nausea, vomiting, and feeling ill. His initial laboratory work was remarkable for blood glucose level of 19 mg/dL, creatinine of 10.41 mg/dL, potassium of 4.3 mmol/L, anion gap of 41 mmol/L, and arterial blood gas with pH of 6.707, pO<sub>2</sub> 163 mmHg, pCO<sub>2</sub> 14 mmHg, and HCO<sub>3</sub> of 2 mmol/L on 2 L of nasal cannula oxygen. The patient was in hypovolemic shock secondary to dehydration, hence requiring vasopressors for a short duration. Among the patient's home medications, it is of significance to mention metformin as a daily medication. He emergently underwent hemodialysis for severe acidosis, with significant improvement in his clinical status. **Conclusion:** Acidosis can occur as a side effect of therapy or synergistic effect of multiple medications. Avapritinib usage along with medications that are known to have potential to cause acidosis, such as metformin, needs to be cautiously administered. Understanding the potential side effects of new therapy in combination with the patient's established medications can facilitate the recognition of potential causal relationships.

**Keywords:** Acidosis, Avapritinib, Dehydration, Metformin

### How to cite this article

Adio B, Darbandi S. A severe case of acidosis with concomitant use of avapritinib and metformin requiring emergent hemodialysis. Case Rep Int 2020;9:100084Z06BA2020.

Article ID: 100084Z06BA2020

\*\*\*\*\*

doi: 10.5348/100084Z06BA2020CR

## INTRODUCTION

Gastrointestinal stromal tumors (GISTs) are rare soft tissue sarcomas of the gastrointestinal tract, with most carrying conserved driver mutations in the tyrosine kinase receptors KIT or platelet-derived growth factor receptor alpha (PDGFRA) [1]. KIT is a type-3 receptor tyrosine kinase (TK) that is frequently mutated at exon 11 or 17 in a variety of cancers [2]. The drug avapritinib (Ayvakit) was approved by the Food and Drug Administration on January 9, 2020 for adults with unresectable or metastatic GIST harboring a PDGFRA exon 18 mutation, including D842V mutations [3]. This medication is specifically indicated for unresectable or metastatic GIST tumors with the stated mutations. The approval of this medication for treatment was based on data from the single-arm, open-label NAVIGATOR trial [3]. Based on the data from the NAVIGATOR trial, exposure-response relationships for any major adverse reaction were observed at higher exposures with a faster time to onset for adverse reactions with increasing avapritinib exposure [3]. The pharmacokinetics of this medication is known to have median time to peak concentration ranging from 2.0 to 4.1 hours following single doses of avapritinib 30 to 400 mg [3].

Babajide Adio<sup>1</sup>, Sepideh Darbandi<sup>1</sup>

**Affiliation:** <sup>1</sup>DO, Internal Medicine Chief Resident, MercyOne North Iowa Internal Medicine Residency, Mason City, Iowa, USA.

**Corresponding Author:** Babajide Adio, DO, 1000 4th St SW, Mason City, IA 50401, USA; Email: badio@atsu.edu

Received: 15 June 2020

Accepted: 27 July 2020

Published: 27 August 2020

With maximum plasma concentration ( $T_{max}$ ) of 2–4 hours, avapritinib is rapidly absorbed and exposure increases linearly with increasing dosages. The most common reported adverse reactions for this medication are edema, nausea, fatigue/asthenia, vomiting, abdominal pain, constipation, and dizziness. In the early phase trial of this medication, avapritinib was noted to be well-tolerated with most adverse events scored as either grade 1 or 2 using doses between 30 and 400 mg daily [4].

There are reported interactions between ayvakit and other medications such as strong and moderate CYP3A inhibitors as these drugs' interaction increases avapritinib plasma concentrations. There are recommendations for medication dose reduction for patients who cannot avoid a moderate CYP3A inhibitor.

Prior findings have shown that exon 11 mutations predominate in GISTs. Avapritinib is a tyrosine kinase inhibitor (TKI) that demonstrates clinical activity in malignancies harboring exon 17 mutations. Recently, a study focused on the budget impact of using avapritinib for treatment of unresectable or metastatic GIST showed minimal budget impact to a US health plan, due to the small patient population and cost savings from reduced post-progression costs [2]. Gastrointestinal stromal tumors represent one of the exceptional cases of solid tumors where the molecular biology is important to understand for medical therapy. Indeed, TKIs are the standard therapy for KIT-mutated GISTs and are expected to be standard for PDGFRA-mutated ones as well.

Pertaining to this case report, it is important to highlight an important adverse event of metformin, which is lactic acidosis that in fact influences treatment strategies in type 2 diabetes mellitus [5].

Here we present a case of a patient who presented with severe acidosis thought to be from metformin toxicity secondary to side effects from a newly started medication.

## CASE REPORT

A 56-year-old male with past medical history significant for GIST of the stomach, essential hypertension, type 2 diabetes mellitus, pulmonary embolism, and bilateral lower extremity deep vein thrombosis (DVT) on apixaban, benign prostatic hypertrophy, gastroesophageal reflux disease, and hyperlipidemia was transferred from an outlying facility for further management of acute renal failure, hypoglycemia, and respiratory failure. The patient had originally presented to the outlying facility with complaints of shortness of breath, nausea, vomiting, and overall feeling poorly since starting avapritinib two weeks prior.

At outlying facility, the patient's initial laboratory work was remarkable for blood glucose level of 19 mg/dL, creatinine of 10.41 mg/dL, potassium of 4.3 mmol/L, anion gap of 41 mmol/L, and arterial blood gas with pH of 6.707,  $pO_2$  163 mmHg,  $pCO_2$  14 mmHg, and  $HCO_3^-$  of 2 mmol/L on 2 L of nasal cannula oxygen. Vital signs

significant for hypothermia of 34.8 °C, bradycardia with heart rate of 50 beats per minute, respiratory rate of 30 breaths per minute, and blood pressure average 170/80 mmHg. The patient was urgently given an amp of D50 with optimal response. Bicarbonate and intravenous fluid resuscitation were initiated, and patient was transferred to our facility. Of significance, the patient was initially neurologically intact on presentation but gradually became confused. Due to impending respiratory failure, he required endotracheal intubation prior to transfer.

The patient's home medications included apixaban 5 mg BID, ferrous sulfate 325 mg daily, gabapentin 100 mg BID, metformin 1000 mg BID, metoprolol tartrate 25 mg BID, pantoprazole 40 mg daily, pravastatin 20 mg daily, amlodipine 5 mg daily, aspirin 81 mg daily.

The patient was admitted to our critical care unit and found to be in hypovolemic shock, requiring norepinephrine to maintain mean arterial pressure >65. Admission blood gas at our facility showed pH of 6.69,  $pCO_2$  39.2 mmHg,  $pO_2$  365 mmHg, and  $HCO_3^-$  4.8 mmol/L. Laboratory work showed creatinine of 10.3 mg/dL, lactate level of 15 mmol/L, and glucose level within normal range of 140–180 mg/dL. Given the severe refractory acidosis to bicarbonate, nephrology was immediately consulted for emergent hemodialysis, and the patient was continued on bicarbonate drip. He was suspected to have severe metabolic acidosis likely in the setting of metformin toxicity. Interestingly, he had been on metformin for a long duration prior to this hospitalization. His home medication of avapritinib was immediately held.

The patient gradually required increased dosages of vasopressors, specifically vasopressin and epinephrine. Despite the shock status, he was able to tolerate emergent dialysis with significant improvement in his creatinine level from 10.3 to 4.64 mg/dL. After the first session of dialysis, bicarbonate improved from admission value of 2–17 mmol/L. Laboratory work improved with the help of volume optimization via hemodialysis, and the patient was monitored closely without dialysis for clinical improvement. With the improvement in the patient, he was able to be extubated shortly after presentation to our facility. After 48 hours in the intensive care unit, he was able to be transferred to the general medical floor.

After the initial admission dialysis session, the patient's kidney function was improved, however, that was not adequate as reported by the nephrology team. Tunnel catheter for dialysis was placed, and the patient received his second dialysis session 72 hours after admission. Throughout patient's hospitalization, contact was made routinely with his medical oncologist at his tertiary center for recommendations on his treatment. For the duration of his hospital stay, avapritinib was held and plans were made to decide on an appropriate regimen for the patient's GIST treatment as outpatient. With clinical and symptomatic improvement, the patient was able to be discharged to home with plans for follow-up with nephrology, oncology, and primary care

physician. Change in his home medication list included discontinuing metformin and avapritinib until follow-ups accordingly.

Shortly after discharge from the hospital, the patient had an outpatient follow-up with his medical oncologist. During the follow-up visits, it was revealed that the patient continued to do well with excellent appetite and very rare nausea. He had required one dialysis session after his hospital discharge, but fortunately his kidney function gradually recovered to the point that his dialysis catheter was removed a month after discharge. Given patient's clinical improvement, his avapritinib was restarted but at a lower dose and only three times weekly. His home medication of metformin was not restarted, and he continued to monitor blood sugar levels with a hemoglobin A1c of 6.2%.

Further follow-up with oncology on the lowered dosage of avapritinib showed the patient was tolerating the prescribed dosage. He had no more episodes of nausea, vomiting, fatigue, or gastrointestinal distress. The dosage of his medication was slowly up titrated to 100 mg once daily. The patient continues to follow with medical oncology closely, and no substitute for patient's home metformin has been started yet given his controlled home blood glucose measurements with lifestyle modifications.

## DISCUSSION

The TKIs have radically changed the treatment course of KIT-driven GISTs. Approved second-line and third-line medical therapies are represented by the TKIs sunitinib and regorafenib, respectively [6].

The relationship between metformin and lactic acidosis is complex, meaning that the use of the drug may be causal, co-responsible, or coincidental. Hemodialysis should systematically be performed in severe forms of lactic acidosis, since it provides both symptomatic and etiological treatment (by eliminating lactate and metformin) [4]. Metformin increases plasma lactate levels in a plasma concentration-dependent manner by inhibiting mitochondrial respiratory predominantly in the liver [7]. Typically, the combination of elevated plasma metformin concentrations (e.g., in renal impaired patients) and a secondary event that disrupts lactate production or clearance (e.g., sepsis or hypoperfusion) are necessary to cause metformin associated lactic acidosis (MALA) [7].

In the case of our patient, he was diagnosed with GIST of the stomach positive for CD 117 with KIT exon 11 mutation in November 2007. Since that year until 2020, he had been treated with multiple immunotherapies including imatinib. Change in treatment was performed after there was an increase in the size of the gastric mass while on imatinib. The patient was subsequently started on sunitinib without

significant clinical improvement. He was then switched to regorafenib but unfortunately increase in liver mass was noted. He was switched to nilotinib therapy based on activating KIT exon 11 mutation, but after two years of therapy, again increase in liver metastasis to portal lymph nodes was noted. He was switched to dasatinib, but experienced side effects of peritonitis and chronic poor wound healing. After one year of treatment with dasatinib and poor clinical progress with increased metastasis, the patient was started on avapritinib 300 mg daily in February 2020.

The interaction between avapritinib and certain drugs has been studied thus far, including itraconazole (a strong CYP3A inhibitor), rifampin (a strong CYP3A inducer), and efavirenz (a moderate CYP3A inducer). Thus far, the interaction between avapritinib and metformin has not been studied to our knowledge; this adds to the uniqueness of this case as unknown interactions could have major adverse outcomes. In other words, no interactions of risk level A or greater are identified between avapritinib and metformin.

A critical potential side effect of avapritinib includes nausea and vomiting, which could have led to dehydration in the setting of patient taking metformin; ultimately, this process could have led to metformin toxicity as a result of renal failure. In the case of our patient, one could argue the theory that his malignancy treatment had the side effects of nausea and vomiting, ultimately leading to dehydration. Although this dehydration is likely the cause of the patient's metformin toxicity, the severity of patient's acidosis is worth discussion for investigation. To date, there is no available literature among the interaction between avapritinib and metformin. Furthermore, upon review of literature, there are no reported direct interaction between chemotherapeutic agents and metformin. Upon further literature review, acidosis is not known to be a side effect of avapritinib.

The use of sodium bicarbonate in MALA is controversial and not fully validated in the clinical scenario of lactic acidosis and hemodynamic instability [8–10]. Prompt treatment of acidosis in our patient with the combination of discontinuation of causing agents, intravenous fluids, bicarbonate, and hemodialysis resulted in a rather quick clinical improvement [2].

## CONCLUSION

Diabetes is above all a vascular disease and metformin is a vascular drug with antidiabetic properties. Avapritinib has a proposed dosing schedule of 300 mg orally once daily until disease progression or unacceptable toxicity. The possible synergistic effect of avapritinib and metformin, or rather more specifically the side effects, in causing toxicity is yet to be studied and potentially can be an avenue of further research.

## REFERENCES

1. Mei L, Smith SC, Faber AC, et al. Gastrointestinal stromal tumors: The GIST of precision medicine. *Trends Cancer* 2018 4(1):74–91.
2. Winger BA, Cortopassi WA, Ruiz DG, et al. ATP-competitive inhibitors midostaurin and avapritinib have distinct resistance profiles in exon 17-mutant KIT. *Cancer Res* 2019;79(16):4283–92.
3. FDA approves avapritinib for gastrointestinal stromal tumor with a rare mutation. [Available at: <https://www.fda.gov/drugs/resources-information-approved-drugs/fda-approves-avapritinib-gastrointestinal-stromal-tumor-rare-mutation>]
4. Lalau JD. Lactic acidosis induced by metformin: Incidence, management and prevention. *Drug Saf* 2010;33(9):727–40.
5. Blough B, Moreland A, Mora A Jr. Metformin-induced lactic acidosis with emphasis on the anion gap. *Proc (Bayl Univ Med Cent)* 2015;28(1):31–3.
6. Gilreath JA, Tchertanov L, Deininger MW. Novel approaches to treating advanced systemic mastocytosis. *Clin Pharmacol* 2019;11:77–92.
7. DeFronzo R, Fleming GA, Chen K, Bicsak TA. Metformin-associated lactic acidosis: Current perspectives on causes and risk. *Metabolism* 2016;65(2):20–9.
8. Elmezughi K, Ekpebegh C. Metformin-associated lactic acidosis treated successfully by peritoneal dialysis in a resource limited setting: Case report. *Pan Afr Med J* 2019;32:112.
9. Park B. Ayvakit approval for GI stromal tumor with PDGFRA mutation. 2020. [Available at: <https://www.gastroenterologyadvisor.com/general-gastroenterology/ayvakit-approval-for-gi-stromal-tumor-with-pdgfra-mutation>]
10. Proudman D, Miller A, Nellesen D, et al. PCN84 budget impact analysis of ayvakit (avapritinib) in patients with gastrointestinal stromal tumors and a PDGFRA exon 18 mutation. *Value in Health* 2020;23(Suppl 1):S38.

\*\*\*\*\*

## Author Contributions

Babajide Adio – Conception of the work, Design of the work, Acquisition of data, Analysis of data, Interpretation

of data, Revising the work critically for important intellectual content, Final approval of the version to be published, Agree to be accountable for all aspects of the work in ensuring that questions related to the accuracy or integrity of any part of the work are appropriately investigated and resolved

Sepideh Darbandi – Design of the work, Acquisition of data, Analysis of data, Interpretation of data, Drafting the work, Revising the work critically for important intellectual content, Final approval of the version to be published, Agree to be accountable for all aspects of the work in ensuring that questions related to the accuracy or integrity of any part of the work are appropriately investigated and resolved

## Guarantor of Submission

The corresponding author is the guarantor of submission.

## Source of Support

None.

## Consent Statement

Written informed consent was obtained from the patient for publication of this article.

## Conflict of Interest

Authors declare no conflict of interest.

## Data Availability

All relevant data are within the paper and its Supporting Information files.

## Copyright

© 2020 Babajide Adio et al. This article is distributed under the terms of Creative Commons Attribution License which permits unrestricted use, distribution and reproduction in any medium provided the original author(s) and original publisher are properly credited. Please see the copyright policy on the journal website for more information.

Access full text article on  
other devices



Access PDF of article on  
other devices







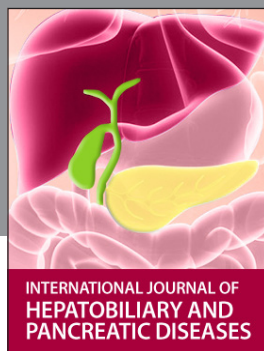INTERNATIONAL JOURNAL OF  
CASE REPORTS AND IMAGES



VIDEO JOURNAL OF  
CLINICAL RESEARCH



VIDEO JOURNAL OF  
BIOMEDICAL SCIENCE




INTERNATIONAL JOURNAL OF  
HEPATOBIILIARY AND  
PANCREATIC DISEASES



INTERNATIONAL JOURNAL OF  
BLOOD TRANSFUSION AND  
IMMUNOHEMATOLOGY



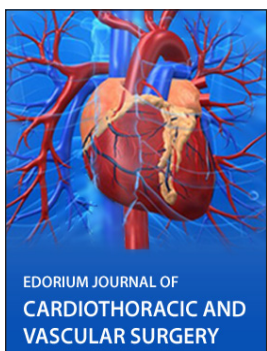EDORIUM JOURNAL OF  
OPHTHALMOLOGY



**Submit your manuscripts at**  
[www.edoriumjournals.com](http://www.edoriumjournals.com)



EDORIUM JOURNAL OF  
MEDICINE



EDORIUM JOURNAL OF  
CARDIOTHORACIC AND  
VASCULAR SURGERY



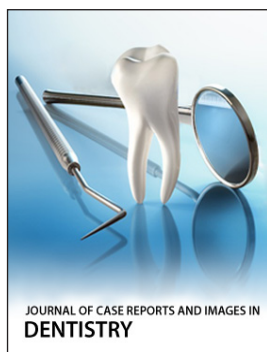
JOURNAL OF CASE REPORTS  
AND IMAGES IN ORTHOPEDICS  
AND RHEUMATOLOGY



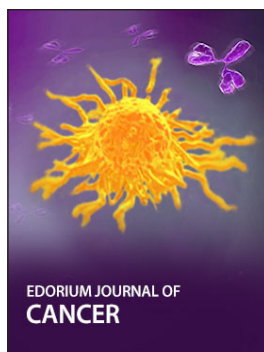EDORIUM JOURNAL OF  
PSYCHOLOGY




EDORIUM JOURNAL OF  
CELL BIOLOGY



JOURNAL OF CASE REPORTS AND IMAGES IN  
DENTISTRY



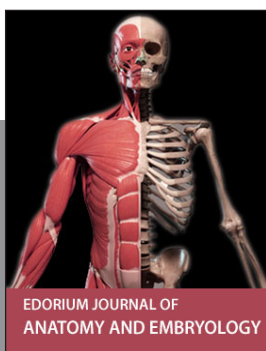EDORIUM JOURNAL OF  
CANCER



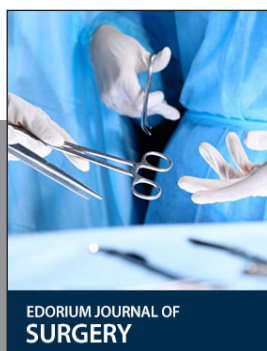
EDORIUM JOURNAL OF  
PSYCHIATRY



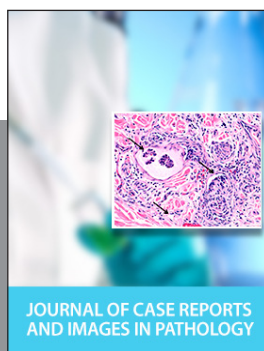JOURNAL OF CASE REPORTS AND  
IMAGES IN INFECTIOUS DISEASES



EDORIUM JOURNAL OF  
ANATOMY AND EMBRYOLOGY



EDORIUM JOURNAL OF  
SURGERY



JOURNAL OF CASE REPORTS  
AND IMAGES IN PATHOLOGY



EDORIUM JOURNAL OF  
ANESTHESIA